

# Heart Hurts Cardiology, P.A.

4512 Chest Pain Highway, Suite 202 • Wilmington, PVC 19999

**Myocardial Perfusion Imaging using a 1-Day Exercise Gated SPECT 99mTC Cardiolite® protocol.**

**PATIENT:** ABNORMAL PATIENT

**DOB:** 06-23-1950

**DATE OF STUDY:** 06-29-2007

**INTERPRETATION DATE:** 08-09-2007

**ORDERING DR:** KAREN HEARTMAN, M.D.

**STRESS MONITOR:** GREG FORD, M.D.

**STRESS INTERPRETER:** GREG FORD, M.D.

**NUCLEAR INTERPRETER:** JUNE JOHNSON, M.D.

**Indications:** Abnormal ECG, and coronary risk factors.

**Age:** 57 **Gender:** female **Height:** 64 inches **Weight:** 158 lbs

**Cardiac Risk Factors:** family history, s/p MI, and tobacco use.

**Cardiac Procedures:** None.

**Medications:** diuretics, and statin drugs.

**Protocol:** Bruce

**Exer. Time:** 7:21

**METS:** 7

**PeakDP:** 27,702

**FuncCapacity:** average

**Study Quality:** good

**ESV:** 19 ml

**EDV:** 67 ml

**Base BP:** 120/72 mmHg

**Peak BP:** 162/71 mmHg

**BP Response:** normal

**HR Response:** accentuated

**Terminated:** achieved target HR.

**Rest Dose:** 11.3 mCi IV

**Stress Dose:** 31.1 mCi IV

**LVEF:** 41 %

**Base HR:** 77 BPM

**Peak HR:** 171 BPM

**Max Predict:** 163 BPM

**HR Achieved:** 105%

**LV size:** normal

**RV uptake:** normal

**TID ratio:**

## FINDINGS:

The resting ECG demonstrates normal sinus rhythm and was entirely within normal limits. There were no ECG changes noted with standing or hyperventilation.

The patient experienced no clinical chest pain during the procedure. The Stress ECG revealed a less than 1 mm upsloping ST-segment change in the inferolateral leads which is non-diagnostic. Stress images reveal a small perfusion abnormality of moderate intensity in the basal-anterior, and mid-anterior wall segments that was reversible on the rest images. Gated SPECT revealed mildly reduced global left ventricular function with an ejection fraction of 41 %. There was mild hypokinesis in the anterior wall of the left ventricle.

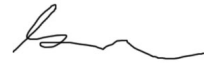
## IMPRESSION:

- 1) Normal clinical response to exercise stress with no chest pain during the procedure.
- 2) Normal electrocardiographic response to exercise stress. The Stress ECG revealed a non-diagnostic ischemic change in the inferolateral leads.
- 3) Myocardial perfusion imaging is mildly abnormal. There is a small area of ischemia in the basal-anterior, and mid-anterior wall segments.
- 4) Overall left ventricular systolic function was mildly reduced with regional wall motion abnormalities noted above.



**June Johnson, MD, FACC**

*Diplomate, Certification Board of Nuclear Cardiology*



**Greg Ford, MD, FACC**

*Diplomate, Certification Board of Nuclear Cardiology*